

**Case Report****Death of Victim Due to Blunt Trauma to the Head**<sup>1</sup>Ibnu Arizona Siregar, <sup>2</sup>Asan Petrus,<sup>1,2</sup>Department of Forensic and Medicolegal Faculty of Medicine, University of Sumatera Utara Medan**ABSTRACT**

**Introduction:** In the 2019-2020 period, the percentage of the Indonesian population who experienced a crime incident and then reported it to the police was no more than 25 percent. In 2020 the percentage was 23.46 percent, a slight increase compared to 2019 (22.19 percent). The Central Statistics Agency released data on the crime rate in Indonesia reaching 94 per 100,000 population in 2020. West Papua is the province with the highest crime rate.

**Case report:** reported a case where the victim was a male corpse, circumcised, known, adult, body length 164 cm, medium stature, black hair, straight shape, easy to remove, The victim was examined at the hospital, based on a letter requesting visum et repertum ( V.E.R) Police No. Police: B/492/VIII/2019/ML with a statement that the body was found by the police/community On Wednesday, August 3, 2019 at 08.00 WIB. The body was then taken to the hospital for external and internal examination of the body (victim).

**Result:** From the results of external and internal examinations, the cause of death of the victim was due to the tearing of brain tissue due to the fracture of the skull bone accompanied by blood infiltration, abrasions, lacerations, fracture of the tongue due to blunt force and advanced decay.

**Discussion:** the high number of unemployed and the difficulty of finding work may be one factor in the increase in the crime rate, with the result that the victim died. Based on the examination carried out on the victim, it was found that there was blood infiltration, abrasions, lacerations, broken tongue bones due to blunt force trauma and the process of decay. carry on. The cause of death of the victim is due to tearing of brain tissue

**Conclusion:** from external and internal examination, it was concluded that the cause of death of the victim was the cause of the death of the victim due to the tearing of brain tissue due to the fracture of the skull bone accompanied by blood infiltration, abrasions, lacerations, fractures of the tongue due to blunt force and advanced decay.

**Keywords:** blunt trauma, tearing of brain tissue

**I. Introduction**

In the 2019-2020 period, the percentage of the Indonesian population who experienced a crime incident and then reported it to the police was no more than 25 percent. In 2020 the percentage was 23.46 percent, a slight increase compared to 2019 (22.19 percent). The Central Statistics Agency released data on the crime rate in Indonesia reaching 94 per 100,000 population in 2020. West Papua is the province with the highest crime rate (*Central Statistics Agency Indonesia.2021*).

Victims of abuse in general, either because of abuse with blunt objects or with sharp objects and a combination of the two, are victims who are mostly served in forensic medical services, in addition to cases of traffic accidents which are also no less numerous. In cases of abuse

with a blunt object, the victim generally can experience bruises or abrasions as well as lacerations and fractures in blunt trauma that is quite hard/strong.

#### A. Bruises and Scratches

Various forms of wound manifestations due to blunt force violence can be in the form of bruises (contusions, hematomas), abrasions (excoriations, abrasions) and open wounds (vulnus laceratum). While some objects that can cause blunt violence are objects with blunt surfaces such as wood, iron, fists and so on. (*Amir A, 2005*)

In bruises, there is bleeding in the tissue under the skin due to the rupture of capillaries and veins, while the surface of the skin or mucous membranes is not injured. This bleeding (hematoma) is blue-black in color which is sometimes accompanied by swelling. In addition, the hematoma that occurs can sometimes give clues about the shape of the object causing it, for example tires, belts, whips, and so on. The size of the hematoma also depends on the strength of the hardness, the subcutaneous tissue and fat tissue as well as age/age factors, diseases (such as hypertension, cardiovascular disease), skin color and blood vessel fragility.

In infants, hematomas tend to occur more easily because of the loose nature of the skin, the thinness of the subcutaneous fat tissue, and so does the elderly who have almost the same condition as the baby. In addition, due to the influence of gravity, the impact of a blunt object on the forehead can cause a palpebral hematoma. From a medicolegal point of view, interpretation of contusions can be important especially if the contusion is accompanied by abrasions or lacerations. With the passage of time, both in the living and in the dead, bruises will form a clearer picture. (*Amir A, 2005; Budiyo A. Widiatmaka W, Atmaja DS, dkk, 1999*)

Blisters occur due to damage to the superficial layer of the skin (epidermis) that occurs as a result of the skin in contact with a blunt or pointed object. Scratches can occur as a result of mechanisms in the form of friction abrasions, pressure abrasions (impressions, impact abrasions), scratch abrasions and grazes. The causes of abrasions are many, for example due to hitting asphalt or a blunt object with a rough surface that touches the skin (*Amir A, 2005; Budiyo A. Widiatmaka W, Atmaja DS, et al, 1999*).

Shear abrasions occur due to linear pressure on the skin accompanied by a sliding motion, for example in cases of hanging or snaring around the neck, as well as in whiplashes. Pressure abrasions are caused by pressing / pressing a blunt object on the skin, for example a curved bite injury. Scratches are caused by sharp objects that scratch and shift the surface of

the skin (epidermis) such as fingernails, the tips of thorns and so on. Meanwhile, shaved abrasions are a variation of scratch abrasions where the area of contact with the skin surface is wider. The direction of violence is determined by looking at the location of the epithelial pile (Budiyanto A. Widiatmaka W, Atmaja DS, et al, 1999). The medico-legal aspects of abrasions include showing the presence of violence, the shape of the tools used, such as scratch marks or bite marks. For the sake of visum et repertum, even though small abrasions are found, they must be observed and recorded because they have medico-legal values that can be useful later. (Amir A, 2005)

#### A. Other Manifestations

In addition to the forms of bruising and abrasions mentioned above, contact with blunt objects can cause skin lacerations and fractures. The laceration can be so severe that it can cause fatal bleeding. Cuts occur due to the contact of a blunt object on the skin which causes the skin to stretch in one direction and exceed the elasticity of the skin. A torn wound is an open wound with the characteristics of an irregular general shape, uneven edges, a bridge of tissue appears between the two edges of the wound, the shape of the base of the wound is irregular and abrasions or bruises are often seen on the side/around the wound.<sup>2,3</sup> Blunt violence strong enough to cause fractures. Regional fractures, especially the head, are blunt trauma that is quite dangerous because it can result in immediate death. (Amir A, 2005; Budiyanto A. Widiatmaka W, Atmaja DS, et al, 1999).

#### A. Blunt Head Trauma

Blunt violence to the head is the most common injury due to accidents and acts of abuse because it is considered a deadly and easily accessible area (Dikshit P.C, 2007). Blunt force on the head can cause skull fractures and bleeding, such as epidural, subdural, subarachnoid and intracerebral hemorrhages. (Wahid S.A, 1993; Dikshit P.C, 2007; Knight B. 1996)

Extradural or epidural hemorrhage is bleeding that occurs between the inner surface of the skull and the outer surface of the dura mater. Bleeding due to rupture of the diploe vein or sinus vein or meningeal artery. The most dangerous epidural hemorrhage is bleeding due to rupture of the victim's middle meningeal artery. Not all epidural hemorrhages are accompanied by skull fractures. The death of the victim was caused by a lot of bleeding that put pressure on the brain, causing an increase in pressure

Subarachnoid hemorrhage may occur as a result of rupture of the vertebral artery. In general, subarachnoid hemorrhage usually originates from a focal contusion/laceration of brain tissue. However, it should also be remembered that this bleeding can also occur spontaneously such as in sunburn (heat stroke), leukemia, tumors, carbon monoxide (CO) poisoning, certain infectious diseases and so on. (Budiyanto A. Widiatmaka W, Atmaja DS, et al, 1999; Wahid S.A, 1993).

Subarachnoid hemorrhage is the most common intracranial hemorrhage. This bleeding occurs between the arachnoid membrane and the pia mater. Blood and bridging veins in the ruptured subarachnoid space mix with the cerebrospinal fluid and spread to areas that are close to even the entire surface of the brain. Subarachnoid haemorrhage resulting from disease is usually a rupture of a berry aneurysm in the circle of Willis. Subarachnoid hemorrhage that occurs due to rupture of the vertebral artery, is caused by a collision or kick to the head which causes maximum stretching of the artery, especially the artery located in the transverse outer foramen of the atlas bone. This type of bleeding is also known as traumatic subarachnoid hemorrhage. (Wahid S.A, 1993)

#### A. Rupture of the Skull Bone

Trauma or blunt force trauma to the head can result in fractures / rupture of the skull bones and result in various complications such as intracranial disorders, bleeding and brain nerve damage. A skull fracture can cause the middle meningeal artery to tear and cause an epidural haemorrhage. Likewise, damage to the cranial nerves contained in the foramen where the nerves enter and leave the skull can occur (Parikh C.K, 1989).

#### A. INTRACRANIAL PRESSURE

The space in the skull is fixed and should not be enlarged. Any disturbance that causes an increase in overall brain size such as epidural hematoma, subdural hematoma, intracerebral hemorrhage, brain neoplasm and so on can cause complications in the form of pressure on the brain. Because tissue in the brain cannot be reduced in size through pressure, the first consequence that occurs due to increased pressure in the brain is a reduction in cerebrospinal fluid in the subarachnoid space and ventricles, in addition to that, a reduction in blood flow to the brain is followed. The amount of cerebrospinal fluid that can be squeezed out is limited. If

the increase in intracranial pressure continues, the blood to the brain will also begin to be disturbed.

Pressure in the brain also causes brain tissue to protrude through the gaps / cavities in the intracranial space such as the foramen magnum, tentorium cerebri and falks cerebri. The suppression of intracranial pressure can press the brain tissue down, it can cause the lower part of the cerebellum to be squeezed out through the foramen magnum. This will mainly cause the medulla oblongata in the brainstem to also be compressed and as a result the respiratory and cardiovascular centers located in that area fail to function. as always. Brain tissue experiencing this condition may show shallow brain gyrus with narrowed sulci due to significant brain edema (Wahid S.A, 1993; Knight B. 1996; Parikh C.K, 1989).

## II. CASE REPORT

A murder case was reported with the victim a 17-year-old male, initials DB, having his address at Jl. Rawe IV Neighborhood VI, Tangkahan sub-district, Medan Labuhan sub-district. The victim was examined at RSU.dr.Pirngadi Medan based on a request letter for visum et repertum (V.E.R) from the Sector Police of the city of Labuhan Deli, dated August 3, 2019 with the number: B/492/VIII/2019/ML, with a written statement that the victim was found on August 3 2011 around 08.00 WIB. The victim was escorted with a visa request letter to RSU.dr.Pirngadi. Based on the VER's request letter, it is requested to carry out an external and internal examination of the body (victim). The examination was carried out on August 4, 2019 at 11.00 WIB.

General Identification : Found a male corpse, circumcised, known, adult, 164 cm long, medium stature, black hair, straight shape, easy to remove.

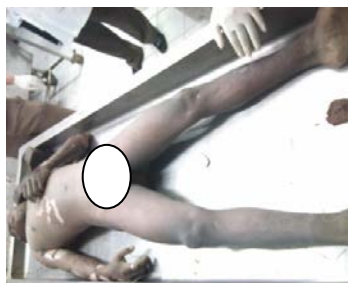


Figure 1. The condition of the victim's body when he arrived at the hospital

In-depth examination of the head, found blood infiltration on the right side of the scalp with a length of 10 cm and a width of 9 cm, with a distance of 5 cm from the midline of the body, 1 cm above the ear.

He found a fractured skull on the upper right with a length of 4 cm and a width of 4 cm with a depth of 1 cm. From the wound, brain tissue was visible.

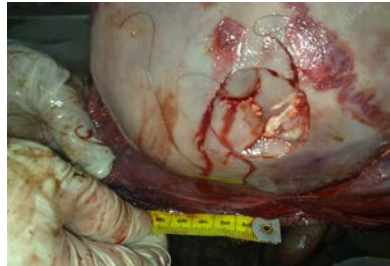

Figure 2. Compression Fracture

At the opening of the skull, it was found that the thick membrane of the right side of the brain was torn apart from the skull fracture with a length of 5 cm and a width of 0.2 cm with a distance of 5 cm from the midline of the body, 5 cm from the right ear.

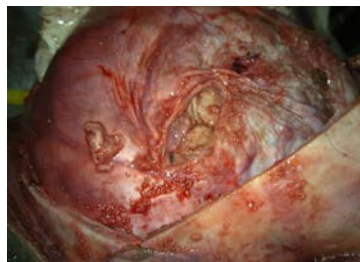

Figure 3. The thick membrane of the brain is torn

A torn brain tissue about the skull fracture was found, 3 cm long and 2 cm wide.

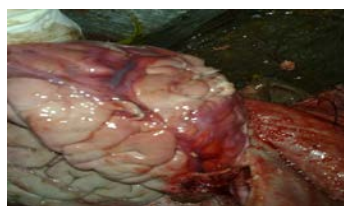

Figure 4. Infiltration of blood

Blood infiltration was found around the torn brain tissue with a length of 20 cm and a width of 8 cm.

On removal of brain tissue, soft brain tissue was found. There was no skull base fracture

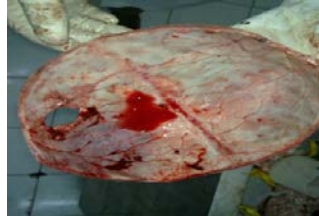

Figure 5. The skull is perforated in the fracture compression area

### III. Discussion

Blunt trauma is trauma caused by contact with a blunt object. Various forms of wounds caused by blunt objects, such as bruises, abrasions, scratches, tears, and even broken bones. Bruises and abrasions are the most common manifestations of blunt trauma. A doctor's examination is carried out to see the medicolegal aspects of each wound, including the direction of trauma, estimates of the source of trauma and so on.

In this case, the results of the examination showed that there were bruises, abrasions and lacerations and cuts and brain tissue rupture due to the fracture of the skull. The trauma experienced by the victim indicated that the victim was subjected to repeated abuse. Fatal blunt trauma injured the victim's head which resulted in the tearing of brain tissue which resulted in the death of the victim.

### BIBLIOGRAPHY

- Amir A. 2005, Trauma Mekanik. Dalam Rangkaian ilmu Kedokteran Forensik. Edisi Kedua. Bagian Ilmu Kedokteran Forensik FK-USU. Medan.
- Budiyanto A. Widiatmaka W, Atmaja DS, dkk. 1999 Traumatologi Forensik. Dalam : Ilmu Kedokteran Forensik, Penerbit Bagian Kedokteran FK-UI, Jakarta
- Dikshit P.C. 2007, Mechanical Injuries. In : PC Dikshit Textbook of Forensic Medicine and Toxicology.
- Knight B. 1996, Head and Spinal Injuries. In : Forensic Pathology. Second Edition. Oxford University Press. Inc. New York,

Muin A.Idris. 1997, Pedoman Ilmu Kedokteran Forensik, Edisi Pertama, Binarupa Aksara, Jakarta

Parikh C.K.1989, Regional Injuries. In :PARKHS Textbook of Medical Jurisprudence & Toxicology. Medikolegal centre. Bombay.

Wahid S.A.1993, Kecelakaan di kawasan Tertentu Tubuh, Dalam Patologi Forensik.Dewan Bahasa dan Pustaka Kementrian Pendidikan Malaysia. Kuala Lumpur,