

Histopathological Effects of Foods Cooked in Microwave Oven on Pancreas of Albino Mice Embryos And The Role of Ginger to Reducing The Damages

Noor S. Al-Tae¹

¹ Koya University, Erbil, Iraq

Abstract

This research aims to study the effect of microwaved food as well as the ability of ginger (*Zingiber officinale*) to treat the adverse effects of microwaved food on embryo's pancreas. Pregnant albino mice (*Mus musculus*) aged (10-14) weeks and weight (25±2) gm., were included fifty pregnant mice were divided into ten groups each one consisted of five pregnant. Pregnant received ginger orally in form of aqueous extract with a single dose (1000mg/kg) body weight. The period of treatment was 18 days starting from the 1st day until 18th day of pregnancy which is the dissecting day. The embryos fixed by Bouin's solution for 48 hr, cut as 5μ and stained with Ehrlich's Haematoxylin & Eosin. Microscopic examination of pancreas showed presence of histopathological changes that increased with the increasing of duration of the exposure. Pancreatic acini were irregular with necrosis and coagulative necrosis the β-cells of langerhan's islets and congestion of blood vessels with infiltration of inflammatory mononuclear cells, especially lymphocytes. In addition to hyperplasia of septa between the lobules. Groups which were treated with ginger extract showed efficient effect in reducing histological changes of the diet cooked by microwave oven in all periods of time that has been used in pancreas.

Keywords: Microwave oven, embryo's pancreas, ginger, *Zingiber officinale*.

1. Introduction

Microwaves refer to the electromagnetic waves in the frequency range of 300 to 300,000 megahertz (MHz) (million cycles per second). Electromagnetic waves are waves of electrical and magnetic energy moving together through space. They include gamma rays, x-rays, ultraviolet radiation, visible light, infrared radiation, microwaves and the less energetic radio waves. Microwaves can pass through materials like glass, paper, plastic and ceramic, and be absorbed by foods and water; but they are reflected by metals [1].

Microwaves have many applications. They are used to detect speeding cars, send telephone, radio and television communications and treat muscle soreness, dry and cure plywood, cure rubber and resins, raise bread and doughnuts, as well as cook potato chips. However, its application in microwave oven is most commonly used by consumers [2]. Food cooked in conventional oven is heated by surrounding hot air whereas food cooked in microwave oven is heated as a result of the alternating electromagnetic field. The electromagnetic field generated is not uniformly distributed inside the cooking cavity and hence it leads to uneven heating of food [1]. Microwave can penetrate to the depth of material, according to the dielectric parameters, thereby heating the material at the same time, both inside and on the surface. Free radicals are generated from many reactions in the body and can be created in foods from a combination of oxygen and light or heat that react with a donor molecule. Therefore, free radicals are not released, but are created. The main target or donor in foods is polyunsaturated fats because they have double bonds that accept oxygen and form a radical. Butter and margarine contain small amounts of polyunsaturated fats. For this reason, free radicals can theoretically occur in them when they are subjected to heat or light in the presence of oxygen. However, these foods also usually contain antioxidants which will reduce the free radicals. The risk of harm associated with microwaving butter or margarine from free radicals is, in my opinion, extremely low [3]. A free radical is defined as any atom or molecule possessing unpaired electrons. Reactive oxygen species are capable of reacting with unsaturated lipids and of initiating the self-perpetuating chain reactions of lipid peroxidation in the membranes [5]. These highly reactive oxygen species can cause extensive tissue damage through reaction with all biological macromolecules e.g. lipids, proteins and nucleic acids, leading to the formation of oxidized substances such as the membrane lipid peroxidation product malondialdehyde [6]. Free radicals can also cause

oxidation of sulphhydryl groups in proteins and strand scission in nucleic acids is also possible [7]. The accumulation of malondialdehyde in tissues or biological fluids is indicative of the extent of free radical generation, oxidative stress and tissue damage [8]. It remains a lot of questions about effects of foods cooked or heated in a microwave oven in the human body, especially for pregnant and embryos, and because of the ginger contain many vitamins and minerals as an anti-oxidants have been chosen in this research to see ginger effect in reducing the side effects of microwaved food in embryo's pancreas.

2. Materials and Methods

Healthy albino mice selected at the age of (10-14) weeks from the two gender, weights rate (25 ± 2) gm. Females placed with males with rate 3:1 per cage in the afternoon, and were sure to get mating in the next morning by observing the vaginal plug [9], pregnant mice isolated in separate cages with writing the date of mating, which was considered zero-day of pregnancy, and the next day is the first day of pregnancy [10]. The breeding and mating process occurred in a large cage enveloped with thick nylon and contains shelves and the temperature inside the cage about 25 C^0 and the light cycle 12 hours light and 12 hours darkness per day. Standard diet used for mice feeding as food negotiable for radiation treatment, using the microwave oven to expose the diet to radiation. Ginger used in form of aqueous extract for rhizomes with dose ($1000\text{ mg}\backslash\text{kg}$) body weight. The pregnant divided into 10 groups as follows:

1st group (control group):

Included 5 pregnant received foods cooked in conventional oven and distilled water only.

2nd, 3rd, 4th and 5th group:

Each group included 5 pregnant received foods cooked in microwave oven (2.45GHz frequency and power of 800 watts) for a period of 2, 4, 6 and 8 minutes respectively and distilled water only.

6th group:

Included 5 pregnant received foods cooked in conventional oven and single dose of ginger extract ($1000\text{ mg}\backslash\text{kg}$) body weight.

7th, 8th, 9th and 10th group:

Each group included 5 pregnant received foods cooked in microwave oven (2.45GHz frequency and power of 800 watts) for a period of 2, 4, 6 and 8 minutes respectively with single dose of ginger extract ($1000\text{ mg}\backslash\text{kg}$) body weight.

All experimental groups anesthetized by ether [10]. Period of treatment 18 days starting from the 1st day until the 18th day of pregnancy. Animals were anesthetized and the embryos fixed in Bouin's solution for 48 hr, cut as 5μ and stained with Ehrlich's Haematoxylin & Eosin [11].

3. Results and Discussion

The majority of islet cells are formed by β -cells which are responsible for producing insulin. Depletion of β -cells will therefore result in insulin deficiency which will lead to a disorder in carbohydrate, protein and fat metabolism with a resultant hyperglycaemia [12].

The microscopic histological examination of embryo's pancreas of pregnant mice that were fed a diet cooked in microwave oven for 2, 4, 6 and 8 minutes for 18 days showed presence of histopathological changes, especially for 6 and 8 minutes treatment. Pancreatic acini were irregular with necrosis of the β -cells of islets of langerhan's (figures (2-3-4-5-6-7-8)) which indicates the presence of damage to the pancreas tissue, which may be caused by oxidative stress, and free radicals that formed in food cooked in microwave oven [3] which causes extensive tissue damage through reaction with all biological macromolecules e.g. lipids, proteins and nucleic acids, leading to the formation of oxidized substances such as the membrane lipid peroxidation product malondialdehyde [5]. Studies shown that free radicals especially oxygen free radicals are instrumental in the development of acute pancreatitis [13]. The results of this study showed occurring coagulative necrosis of some β -cells of langerhan's islets (figures (2-3-4-5-6-7-8)) which occurs due to the acute toxicity of some toxic substances or due to the acute anoxia like that happens from clogging blood flow [14]. This indicates that the diet cooked in microwave oven causes significant disruption in the metabolic processes of the β -cells of langerhan's islets in detoxification. The results of this study also

indicated to the congestion of blood vessels (figures (2-3-4-5-6-7-8)) which arises from clogging physicist of any small or large blood vessels or arising from the Inability to rush blood flow forward and thus the blood accumulates in the vessels and appears in the form of congestion [14]. Results also showed infiltration of inflammatory cells monocyte around the central veins (figures (2-3-4-5-6-7-8)) which caused by migration of leukocytes, mainly neutrophils and macrophages, outside of the blood vessels (extravasation) into the tissue, and the intensity of migration of these cells depends on the intensity of the histological damage [15]. This indicates that exposing diet to microwave radiation effect on the food ingredients and leads to the formation of the components differ significantly from foods components is non-exposing to microwave and this is consistent with what he found [3]. In the heating or cooking foods in the microwave oven affect the nutritional components and lead to the formation of new compounds of the most important free radicals, especially when you reach the high temperatures. This is also consistent with our study; it was observed that the pathological changes increase with the length of time where it was more severe at 8 minutes. This study agrees with findings of [16] where noted that food exposed to microwave radiation causes histological changes in testes of male rabbits. The present results also agree with [17] which confirmed that microwaved food affects the oxidative state of the liver and brain macromolecules. Damage caused by free radicals is aggravated by a reduction in protective antioxidant enzymes caused by the microwave interactions in biological tissues leads to production of reactive oxygen species that eventually affect the status of the measured physiological parameters. While the histological sections of the embryo's pancreas of animals treated with extract of ginger have shown the existence of simple necrosis the β -cells of langerhan's islets (figure (9)). These results not agree with [18] that observed no histological changes in embryos when treated female rats with ginger. This study also inconsistent with [19] that ginger extract (100mg/kg, 250mg/kg and 500mg/kg body weight) showed normal exocrine part and disintegration of the islet cells of langerhans with pyknotic nuclei, this study showed that the effect on the islet of langerhan increases as the consumption increases. The reason for this may be these researchers using dose less than

the dose that used in our research. Whilst histological examination of the embryo's pancreas fed on a diet cooked in microwave oven after-treatment of ginger extract showed amelioration in histological changes (figures (10-11)). This reflects the positive impact of the components of ginger extract as an anti-oxidant and the most important of which Gingerol and Shogaols which may have a role in sweeping free radicals [20]. As well as ginger rhizomes contain a high level of vitamin C, which is one of stronger natural antioxidants [21]. Where is an important free radical scavenger in extracellular fluids, trapping radicals and protecting biomembranes from peroxide damage. Vitamin C effectively scavenges singlet oxygen, super-oxide, hydroxyl, water soluble peroxy radical and hypochlorous acid. It is also reported to be an excellent source of electrons and therefore can donate electrons to free radicals such as hydroxyl and super oxide radicals and quench their activity. Vitamin C is an essential co-factor involved in many biochemical functions and acts as an electron donor or reducing agent [22]. It was found that treatment with vitamin C especially when mixed with vitamin E, selenium, and methionine reduces chronic pancreatitis [23]. Moreover, ginger has an ability to increase the intracellular activities of SOD, CAT and GSH enzymes and has synergistically combats oxidative stress by scavenging free radicals and/or augmenting endogenous antioxidant activities [24]. These results consistent with the study of [16] that used *Sesamum indicum* seeds in concentration (1000 mg/kg ration) as an anti-oxidant to reduce the histological changes in testes of male rabbits, where noticed that *Sesamum indicum* seeds decrease the histological changes in testes. These results are agree with the findings of [25] that gingerol one of the active components of ginger appeared to inhibit and intervene cyto-degeneration of pancreatic β -cells and helped in scavenging the free radicals. It also agreed with the findings of the [26] that ginger has been shown to modulate insulin release in pancreatic β -cells and reported that gingerol which is an active component of ginger it showed a protective effects of pancreatic β -cells. This study also agrees with the findings of [27] that ginger extract (400mg/kg body weight) minimized the histopathological in pancreas of rats treated with aflatoxin. It also agrees with [28] that refer to the ginger extract reduced the damages of diabetic rats especially when mixed with curcumin. It was also agree with [29] that ginger extract

(500mg/kg body weight) decrease the histological changes in pancreas of diabetes mellitus induced by streptozotocin in rats.

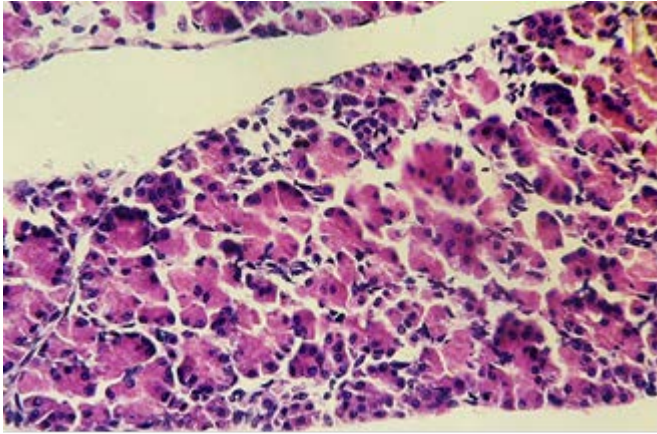


Figure (1): Histological section in the pancreas of mouse embryo fed on diet cooked in conventional oven shows normal tissue (HE - 400X).

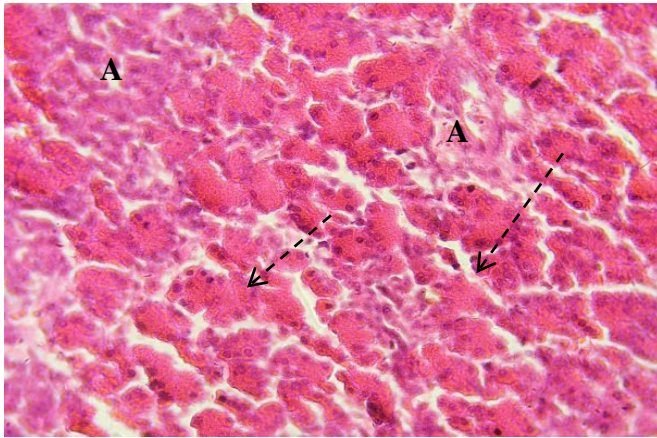


Figure (2): Histological section in the pancreas of mouse embryo fed on diet cooked in microwave oven for 2 minutes shows, hyperplasia of septa (A), necrosis the β -cells of langerhan’s islets (HE - 400X).

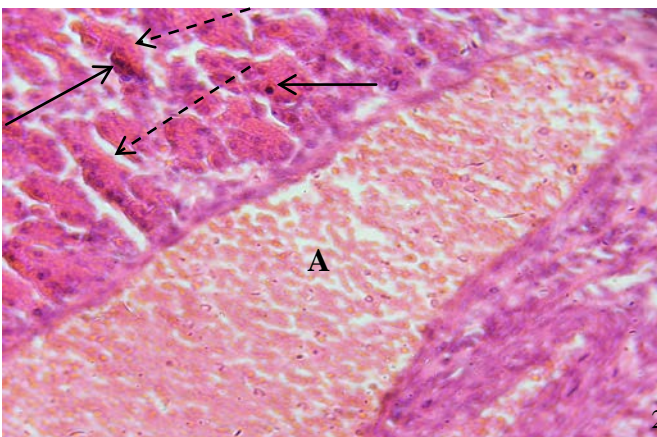


Figure (3): Histological section in the pancreas of mouse embryo fed on diet cooked in microwave oven for 4 minutes shows, expansion and congestion of the blood vessel (A), necrosis the β -cells of langerhan’s islets and coagulative necrosis of other β -cells (HE - 400X).

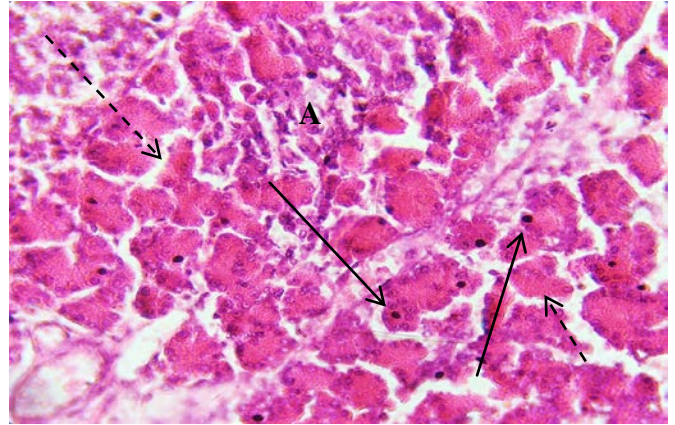

Figure (4): Histological section in the pancreas of mouse embryo fed on diet cooked in microwave oven for 6 minutes shows, hyperplasia of septa (A), necrosis the β -cells of langerhan’s islets and coagulative necrosis of other β -cells (HE - 400X).

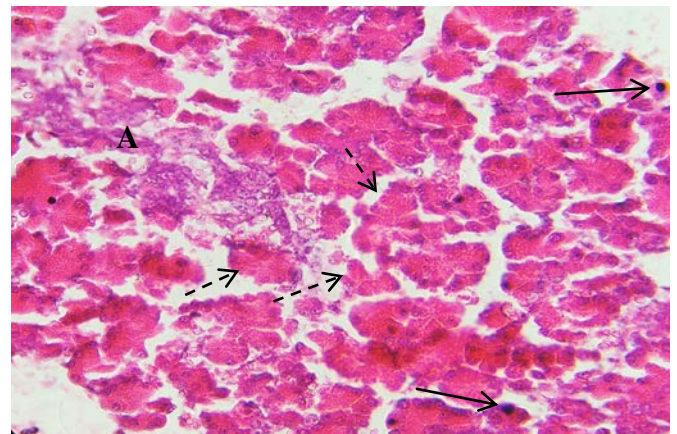


Figure (5): Histological section in the pancreas of mouse embryo fed on diet cooked in microwave oven for 6 minutes shows, hyperplasia of septa (A), necrosis the β -cells of langerhan's islets and coagulative necrosis of other β -cells (HE - 400X).

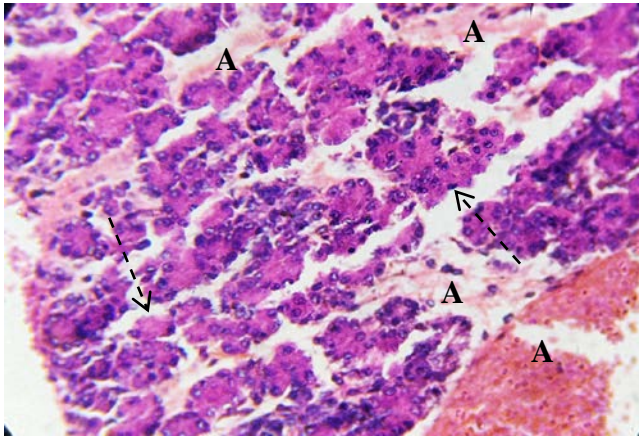


Figure (6): Histological section in the pancreas of mouse embryo fed on diet cooked in microwave oven for 8 minutes shows, hemorrhage interacinous (A), necrosis the β -cells of langerhan's islets (HE - 400X).

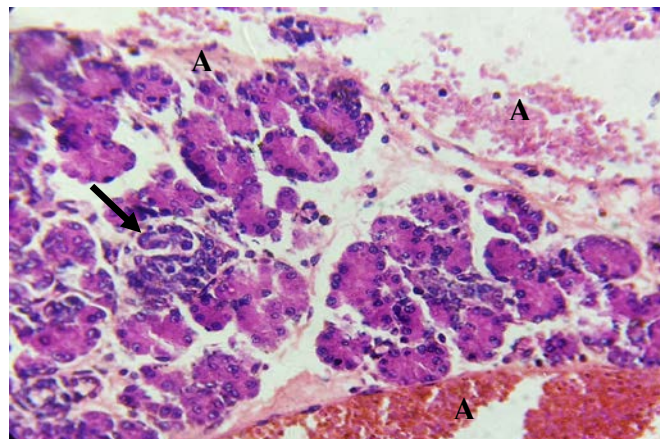


Figure (7): Histological section in the pancreas of mouse embryo fed on diet cooked in microwave oven for 8 minutes shows, hemorrhage interacinous (A), focal infiltration of inflammatory cells (HE - 400X).

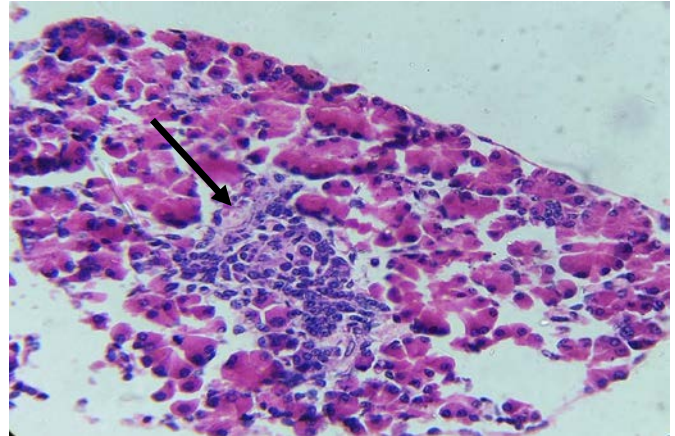


Figure (8): Histological section in the pancreas of mouse embryo fed on diet cooked in microwave oven for 8 minutes shows, focal infiltration of inflammatory cells (HE - 400X).

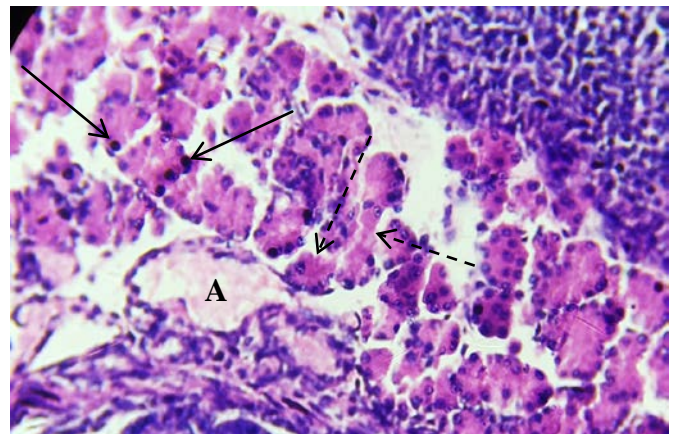


Figure (9): Histological section in the pancreas of mouse embryo fed on diet cooked in conventional oven with ginger shows, simple congestion (A), simple necrosis the β -cells of langerhan's islets and simple coagulative necrosis of other β -cells (HE - 400X).

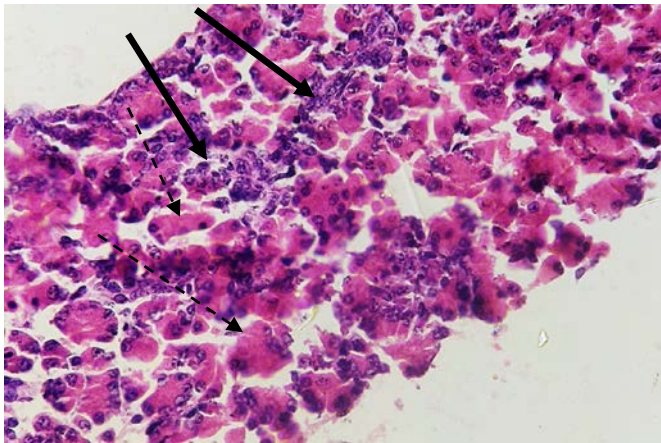


Figure (10): Histological section in the pancreas of mouse embryo fed on diet cooked in microwave oven for 6 minutes treated with ginger shows, simple necrosis the β -cells of langerhan's islets and few infiltration of inflammatory cells (HE - 400X).

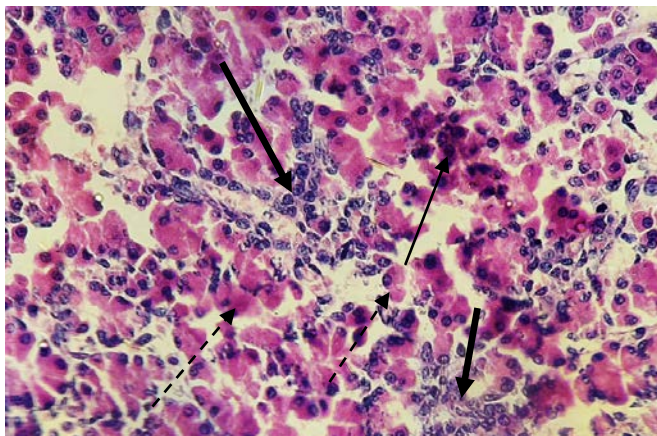


Figure (11): Histological section in the pancreas of mouse embryo fed on diet cooked in microwave oven for 8 minutes treated with ginger shows, simple necrosis the β -cells of langerhan's islets simple coagulative necrosis and few infiltration of inflammatory cells (HE - 400X)

4. Conclusions

The cooked food or heated using a microwave oven effect on the food components and leads to the formation of the components differ from the components of the food before it is heated, for example, free radicals, as well as turning some of the essential vitamins from the active form to the inactive form, and this effect reflected negatively on the body, especially pregnant women and their embryos. The length of time for cooking or heating relation to pathological changes. The effect of ginger as an anti-oxidant was able to reduce many of the pathological changes caused by eating foods cooked by microwave oven.

References

- [1] Hill, A and ILSI Europe "Microwave Oven Task Force. Microwave Ovens". Brussels: ILSI Europe; 1998.
- [2] Wayne, A. and Newell, L. "The Hidden Hazards of Microwave Cooking". Herbal Healer Academy Inc. The Christian law institute, 2004.
- [3] Sumnu, G., "A review on microwave baking of foods". INT. J. Food Sci. Technol., 36: 117-127, 2001.
- [4] Salvemini, D. and Cuzzocrea, S. "Therapeutic potential of superoxide dismutase mimetics as therapeutic agents in critical care medicine" Crit Care Med., 31(1):S29-S38, 2003.
- [5] Srivastava1, A.N.; Gupta, A.; Srivastava, S.; Natu, S.M.; Mittal, B.; Negi, M.P.S. and Prasad, R. "Cisplatin Combination Chemotherapy Induces Oxidative Stress in Advance Non Small Cell Lung Cancer Patients" Asian Pacific J Cancer Prev, 11: 465-471, 2010.
- [6] Kaul, N.; Siveski-iliskovic, N.; Hill, M.; Slezak, J. and Singal, P.K. "Free radicals and the heart". J Pharmacol Toxicol Methods, 30:55– 67, 1993.
- [7] Gutteridge, J.M. "Lipid peroxidation and antioxidants as biomarkers of tissue damage" Clin Chem., 41:1819-28, 1995.

- [8] Sainani, G.S.; Sawhney, M.J. and Sainani, R.G. "Oxidative stress: A key factor in the pathogenesis of chronic diseases" *Med Update*, 7:1-5, 1997.
- [9] Meirrow, D.; Epstein, M.; Lewis, H.; Nugent, D. and Gosden, R.G. "Administration of Cyclophosphamide at Different Stages of Follicular Maturation in Mice: Effects on Reproductive Performance and Fetal Malformations" *Hum. Reprod.*, 16(4):632-637, 2001.
- [10] Correia-Pinto, J.; Tavares, M.T.; Baptista, M.J.; Estevao-Costa, J. and Flake, A.W., "A New Fetal Rat Model of Gastroschisis: Development and Early Characterization" *J. Ped. Surg.*, 36(1):213-216, 2001.
- [11] Bancroft, J.D. and Cook, H.C. (1998) "Manual of histotechnological techniques" Edited by: Churchill Livingstone., New York, 1998.
- [12] Eliakim-Ikechukwu, C.F. and Obri, A.I. "Histological Changes In The Pancreas Following Administration Of Ethanolic Extract Of Alchornea Cordifolia Leaf In Alloxan Induced Diabetic Wistar Rats." *Nigerian Journal of Physiological Sciences*, 24 (2): 153 -155, 2009.
- [13] Schoenberg, M.H.; Buchler, M.; Gaspar, M.; Stinner, A.; Younes, M.; Melzner, I.; Bultmann, B. and Beger, H.G. "Oxygen free radicals in acute pancreatitis of the rat" *Gut*, 31:1138-1143, 1990.
- [14] Stevens, A.; Lowe, J.S.; Young, B. and Deakin, P.J. "Wheater's basic histopathology: a colour atlas and text" (4th ed.). Edinburgh: Churchill Livingstone, 2002.
- [15] Kumar, V.; Abul Abbas, K. and Fausto, N. "Robbins and Cotran Pathologic Basis Of Disease" (7th ed) Philadelphia: Saunders Company, 2005.
- [16] AL-Hadidy, A.A. "The Effect of Sesamum indicum Seeds on some Physiological, Biochemical and Histological Features in Local Male Rabbits that Fed by Ration Exposed to Radiation". *College Of Basic Education Researches Journal*. 11(2):612-628, 2011.
- [17] Ajayi, F.A.; Afolabi, R.O.; Chukwudozie, C.N. and Osuntoki, A.A "Consumption of Microwaved Food induces Oxidative Stress in the Liver and Brain of Sprague-Dawley Rats" *IOSR-JESTFT*, 8(7): 21-24, 2014.
- [18] Abu Baker, S.O. "Effect of Ginger on the Histological Structure of Some Organs of Female Rats and Their Embryos during Pregnancy" *Life Science Journal*, 10(2): 1225-1232, 2013.
- [19] Udo-Affah; Gabriel, U.; Eru; Eru, M.; Ede, P.O. and Uruakpa, K.C. "Disintegration Of The Islet Cells (Of Langerhans) Following The Administration Of Ethanolic Extract Of Ginger In Adult Wistar Rats". *European Journal of Biology and Medical Science Research*. 3(3):1-6, 2015.
- [20] Zhan, K., Wang, C., Xu, K. and Yin, H. "Analysis of volatile and non-volatile compositions in ginger oleoresin by gas chromatography mass spectrometry". *Se. Pu.*, 26: 692-696, 2008.
- [21] Sade, F.O. and Aderonke, A.O. "Physicochemical properties, vitamins, antioxidant activities and amino acid composition of ginger spiced maize snack 'kokoro' enriched with soy flour (a Nigeria based snack)" *Agricultural Sciences*, 4(5B):73-77, 2013.
- [22] Adikwu, E. and Deo, O. "Hepatoprotective Effect of Vitamin C (Ascorbic Acid)" *Pharmacology & Pharmacy*, 4, 84-92, 2013.
- [23] Khariong, P.D.S.; Hajong, R.; Kundu, D.; Tongper, D.; Mibang, N. and Picardo, P.J. "A Comparative Study into Pain Treatment in Chronic Pancreatitis between Non Operative Conventional Treatment and Those Treated With Antioxidants" *Journal of Dental and Medical Sciences*. 6(6):91-99, 2013.
- [24] Shobana, S. and Akhilender, N.K. "Antioxidant activity of selected Indian spices" *Prostagl. Leuk. Esse. Fatty Acids*, 62 : 107-110, 2000.
- [25] Aggarwal, B.B. (2010) "Targeting inflammation-induced obesity and metabolic diseases by curcumin and other nutraceuticals" *Annu. Rev. Nutr.*, 30:173-199, 2010.
- [26] Chakraborty, D.; Mukherjee, A.; Sikdar, S.; Paul, A.; Ghosh, S. and Khuda-Bukhsh A.R. "[6]-Gingerol isolated from ginger attenuates sodium arsenite induced oxidative stress and plays a corrective role in improving insulin signaling in mice" *Toxicolo. Letters*, 210: 34- 43, 2012.
- [27] Abd El-Haleem, M.R and Mohamed, D.A. "The effects of experimental aflatoxicosis on the pancreas of adult male albino rats and the role of ginger supplementation: a histological and biochemical study" *The Egyptian Journal of Histology*. 34:423-435, 2011.
- [28] Khattab, H.A.H; Al-Amoudi, N.S. and Al-Faleh, A.A. " Effect of Ginger, Curcumin and Their Mixture on Blood Glucose and Lipids in



Diabetic Rats" Life Science Journal. 10(4):428-442, 2013.

- [29] Faried, M.A.; Mansour, F.K.; Zolfakar, A.S. and El-Kholy, W.B "Protective Role of Ginger on the Induced Diabetic Retinopathy in Adult Albino Rats" Journal of American Science 10(10):134-152, 2014.

Author

Noor S. Al-Tae - Biology Dept. \ Faculty of Science and Health \ Koya Univ. \Iraq-Kurdistan region (phone: +064-7711743571; +064-7515416194;

G.mail: Noor.subhy@koyauniversity.org

<https://koyauniversity.org/noor-subhy/>